

Fibreoptic intubation

Sarah Barnett*, Irene Bouras, Simon Clarke

*Correspondence email: sarahfbarnett@googlemail.com

INTRODUCTION

Awake fibreoptic tracheal intubation is a valuable technique that achieves safe airway management of patients who have known or potential difficult direct laryngoscopy. It is a skill in which most anaesthetists would like to be proficient, however, due to a perceived lack of opportunities, a large proportion are not confident in performing this type of laryngoscopy.

Fibreoptic intubation can be performed on awake or anaesthetised patients. An awake technique is chosen when it is considered unsafe to anaesthetise the patient before guaranteeing the ability to secure their airway, usually when difficult laryngoscopy and difficult bag-mask ventilation are expected. Table 1 shows the vital steps in this procedure.

Table 1. Ten essential steps to performing awake fibreoptic intubation

1. Ensure appropriate indication
2. Explain procedure to patient and give premedication as appropriate
3. Prepare equipment; assemble and check fibrescope, railroad endotracheal tube (ETT) over fibrescope, prepare local anaesthetic solutions
4. Monitoring, oxygen, intravenous access
5. Commence sedation if being used
6. Position patient and ensure appropriate level of sedation
7. Anaesthetise airway
8. Perform intubation
9. Confirm correct ETT position
10. Administer general anaesthesia

PATIENT SELECTION

The principal indication for awake fibreoptic intubation is patient safety in the setting of a documented history of difficult intubation and/or facemask ventilation. Other indications include:

- patients at risk of aspiration of gastric contents (unfasted or severe reflux) who require intubation but are known or potentially difficult to intubate, and

- situations where it is beneficial to assess a patient's neurological status after intubation, but prior to surgery, for example those with an unstable cervical spine injury.

As with any procedure, there are contraindications to performing the technique, particularly patient refusal or non-compliance with the technique.

Table 2. Contraindications to awake fibreoptic intubation

Patient refusal
Inexperience
Local anaesthetic sensitivity
Non-compliance / uncooperative e.g. children, special needs patients
Airway bleeding
Critical airway (see below)

A patient with stridor has an airway that may become obstructed with minimal provocation (sometimes termed a 'critical airway'). This is a relative contraindication to the technique - insertion of a fibreoptic scope through the narrowest part of the airway may cause complete obstruction. Therefore in cases of severe upper airway obstruction alternative techniques, such as inspection under deep inhalational anaesthesia or awake tracheostomy, should be considered to secure the airway. In cases of airway bleeding, whether due to trauma or tumour, a fibreoptic approach to intubation is not advised as the blood obscures the field of vision.

ORAL OR NASAL APPROACH

Awake fibreoptic intubation can be performed via the mouth or the nose. Many anaesthetists prefer the nasal approach initially, as this tends to offer an easier line of access to the larynx and it is usually better tolerated by patients. Nasal pathology and a current or previous history of epistaxis are contraindications to this route.

The mouth has a greater volume than the nose, but it can be easier to stray from the midline position when inserting the scope. In this situation a split oral airway (Berman or Ovassapian – Figure 1) can help.

Summary

Awake fibreoptic intubation is a useful technique where difficult intubation is anticipated on the basis of airway examination or previous anaesthesia. Intubating fibrescopes are not universally available, but are increasingly found in resource poor settings as donated equipment. The indications, contraindications, equipment and preparation required for awake fibreoptic intubation are discussed. Sedation is desirable although not essential and the drugs used to achieve this depend largely on availability. Adequate anaesthesia of the airway is essential for a safe successful procedure and we describe our preferred technique along with alternatives.

Sarah Barnett
Perioperative Clinical
Research Fellow

Irene Bouras
Locum Consultant
Anaesthetist

Simon Clarke
Consultant Anaesthetist
University College London
Hospital
London NW1 2BU
UK

Avoid oral intubation if there is major oral pathology or the tube will interfere with surgical access.



Figure 1. Berman Airway - These airways are similar to conventional oropharyngeal airways, the difference being that they allow passage of both the fibroscope and the railroaded endotracheal tube. Their design allows them to be removed from the mouth without dislodging the fibroscope or the tube.

PREPARATION - EQUIPMENT

Ensure that prior to commencing anaesthesia your room is fully equipped with an anaesthetic machine, suction, tilting patient trolley, emergency drugs and equipment for cricothyroid puncture. This is essential to achieving smooth and efficient conduct of the awake intubation. A skilled assistant, with prior experience of this procedure, will be required to help you. It is also useful to have a third member of staff to support and reassure the patient during the procedure.

Fibroscope (Figure 2)

It is important that you, as the operator, can set up the scope and monitor. The steps required to do this are as follows:

1. Ensure there is a functioning light source that is compatible with the fibroscopic scope.
2. Focus the fibroscopic laryngoscope by visualising fine print.
3. Attach the camera (if you have one) and refocus the camera lens.
4. Perform a 'white balance' if you are using a camera.
5. Make sure that the camera is orientated correctly by ensuring the black triangle (or other marker in the visual field of the scope) is at the 12 o'clock position.
6. Load the endotracheal tube (ETT) onto scope, securing it with a small piece of tape (Figure 3)




Figure 2. The fibroscopic scope

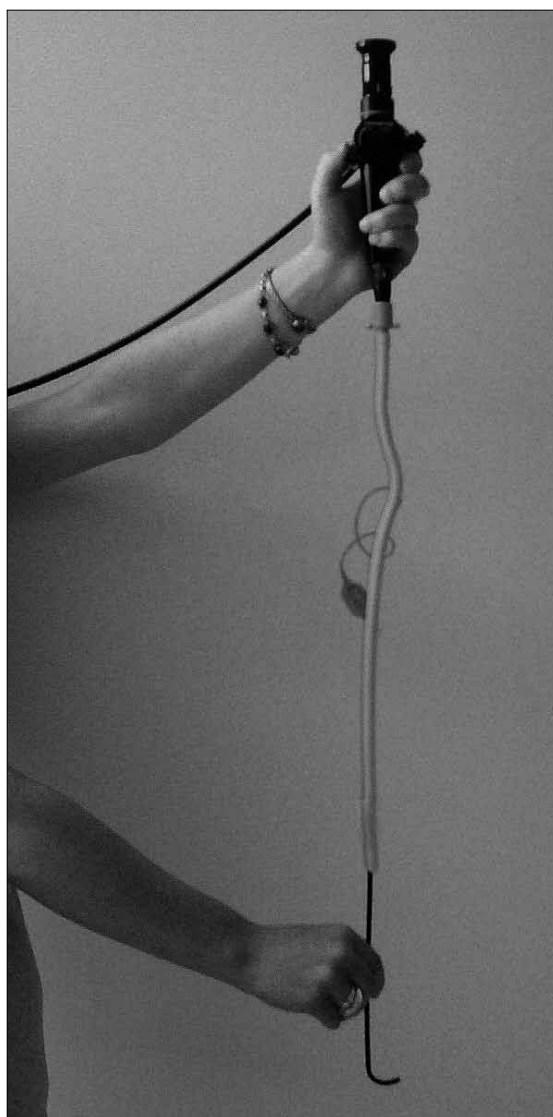


Figure 3. Fibroscopic scope loaded with north-facing Portex endotracheal tube

Sterile gloves should be worn when handling the fibroscope. The fibroscope should always be held at its most distal point (i.e. as close as possible to the patients' nose or mouth as possible) and be kept straight to avoid kinking and fracture of the fiberoptic strands contained within it. Hold the scope in your dominant hand with the lever on the control body pointing towards you; in this configuration moving the lever up with your thumb will move the tip of the scope down, and moving the lever down with your thumb down will move the tip up. There are three possible movements:

1. tip up/down,
2. scope inserted deeper or withdrawn,
3. clockwise/anticlockwise rotation of the scope. If the scope is kept straight the rotation of the control end will cause exactly the same movement of the tip

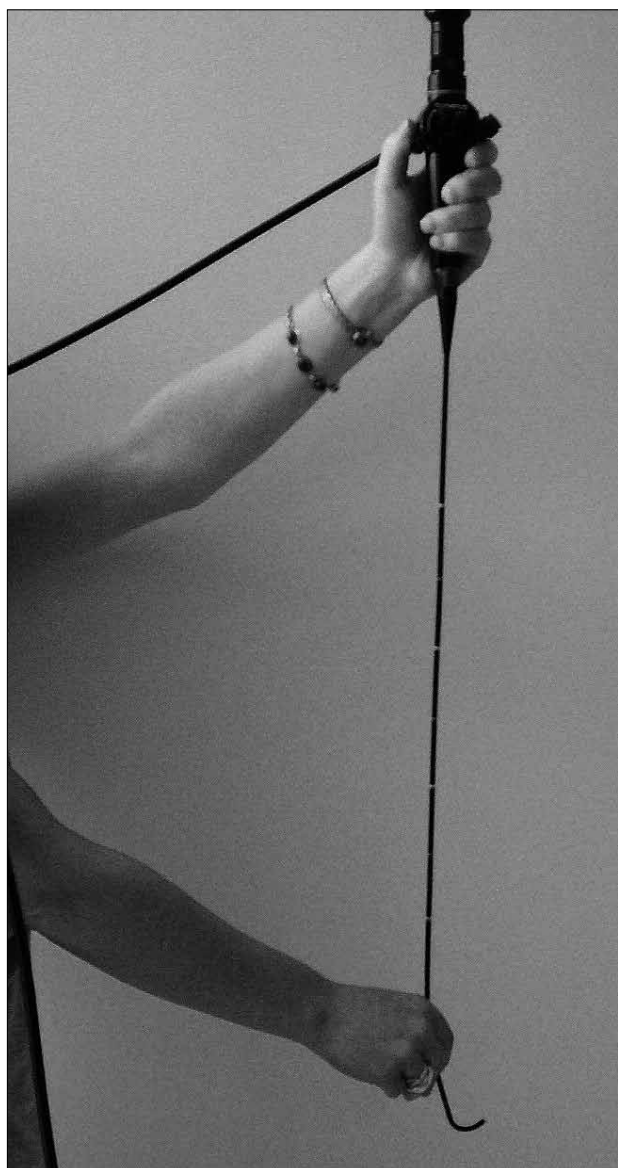


Figure 4. Looking to the left is achieved by elevating the tip (i.e. lever down, tip up) and rotating the scope 90° anticlockwise or by depressing the tip (i.e. lever up, tip down) and rotating 90° clockwise

The fiberoptic scope usually has a 1.0 - 1.5mm working channel but suctioning of secretions is often ineffective through a port of such a narrow calibre. Careful suctioning of the mouth with a Yankeur sucker (or of the nose with fine bore suction catheter) will often clear secretions more reliably. This is generally well tolerated after application of topical local anaesthetic (see later).

Endotracheal tube (ETT)

The choice of endotracheal tube depends upon the clinical situation and tube availability. Reinforced ETTs are commonly used (e.g. Mallinckrodt), which can be placed orally or nasally. The ETT that comes with the intubating Laryngeal Mask (ILMA) has a curved Tuohy style tip, allowing the leading edge of the tube to run closer along the scope when it is pushed over it. This reduces the likelihood that the tube will get caught at the arytenoids or vocal cords (Figure 5).

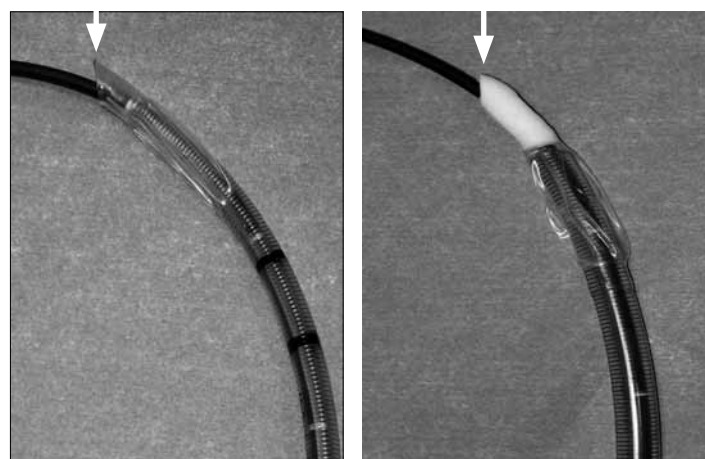


Figure 5. Different profile of an armoured ETT (on the left) with a prominent 'lip', as indicated by the arrow and an ILMA tube (on the right)

North facing Portex nasal tubes, (typically size 6 for females and 6.5 for males) are often used for maxillo-facial procedures. These tubes are made of soft material. The catheter mount connection is positioned away from the surgical field, thereby improving surgical access.



Figure 6. Portex north-facing nasal tube

PREPARATION OF THE PATIENT

General aspects

Appropriate preparation of the patient is a key factor in achieving a calm and controlled environment to perform a successful awake

intubation. The procedure should be explained and consent obtained. Explain to the patient that sedation is not anaesthesia and some degree of recall for events is possible. They may have undergone the procedure before so it is important to know whether this was a good or bad experience.

Full monitoring should be applied before starting the procedure.

An anti-sialogogue is generally recommended to reduce secretions that may obscure the fiberoptic view. Dry mucous membranes may also allow the topicalisation with local anaesthetic to work more effectively. Glycopyrronium is usually used and it can be given subcutaneously or intramuscularly an hour before the intubation. Alternatively it can be given intravenously when the patient arrives in the anaesthetic room. The standard dose is 4mcg.kg^{-1} for all routes. Atropine (20mcg.kg^{-1} to a maximum of 500mcg) is a suitable alternative.

Patient and operator position (Figure 7)

The patient can be positioned sitting up, with the operator facing the patient, or lying supine with the operator standing behind the patient at the head of the trolley. The choice is usually influenced by prior experience - many anaesthetists will be more comfortable at the head of the bed, whereas most physician bronchoscopists stand facing the patient. If you use an unfamiliar position the image you see will be inverted.

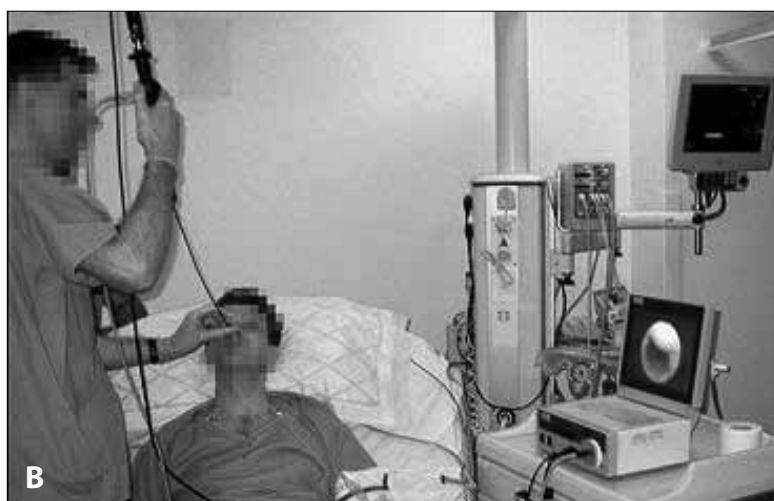
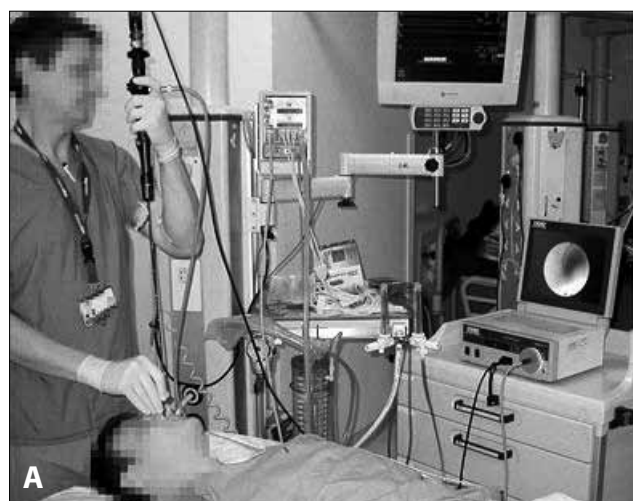
Figure 7. Intubation with the operator standing behind the patient (A) and in front of the patient (B)

Table 3. Benefits of the sitting and supine position

Benefits of sitting position

(Operator in front)

- Eye contact between patient and operator
- Less pooling of secretions
- More comfortable for operator (i.e. less tiring on operating arm)
- More comfortable for patient
- Airway more open / patent
- Better patient ventilation e.g. COPD

OXYGEN DELIVERY

Oxygenation during the procedure is important, especially if administering sedation. It may be slightly awkward to adequately oxygenate the patient while maintaining access for instrumentation of the nose or mouth. Helpful devices include single nasal prongs, a nasal sponge (Figure 8) or a Hudson facemask cut appropriately to allow access to the nostril of the patient.




Figure 8. Nasal sponge

SEDATION

Sedative drugs and techniques

Provided that safety is not compromised, conscious sedation is desirable to minimise awareness of the procedure. Remember that

Benefits of supine position

(Operator behind)

- Familiarity with position
- Good line of access
- Better for patients unable to sit up e.g. cervical spine injury

good local anaesthesia is the essential ingredient in this technique and avoidance of sedation may be the safest option in some settings for some patients. The goal is to provide analgesia and amnesia in a calm and cooperative patient who can follow verbal commands while maintaining a patent airway, adequate oxygenation and ventilation. Some degree of airway reflex and cough suppression is also beneficial.

There are a variety of sedation techniques used by anaesthetists and choice is largely determined by availability. There is no single ideal agent. Fentanyl and alfentanil are commonly used. An infusion of remifentanyl has become popular in UK due to its advantageous pharmacokinetic profile. It has a constant context sensitive half-time, which means that it does not accumulate and once the infusion stops the analgesic and sedative effect wears off quickly. Sedation with ketamine² has been described, either used alone or in conjunction with other drugs.

Remifentanyl provides good conditions for the patient and operator with its analgesic, antitussive and sedative properties. This, combined with its short duration of action allows appropriate titration to the stimulation associated with airway manipulation. Caution is required when using this drug as apnoeas are not always obvious and can occur when the patient appears to be 'awake'. Capnography and a gentle reminder to 'breathe' can help to avert this situation.

A recent study demonstrated similar satisfaction scores by patients when comparing remifentanyl to propofol despite a higher level of recall when using remifentanyl.³

The table below illustrates some of the possible drug regimens which can be used for sedation. Approximate dose ranges are included, but the actual dose required may vary depending upon the age and physiological status of the patient. All drugs should be administered cautiously and titrated to effect.

Table 4. Suggested dosing regimens for some sedative drugs

Drug	Dosage
Propofol	<i>Target controlled infusion:</i> Start with a target of 0.75-1.5mcg.ml ⁻¹ and adjust by 0.25-0.5mcg.ml ⁻¹ <i>Simple infusion:</i> Start with a 1% propofol solution running at 10ml.h ⁻¹ and titrate up to 30ml.h ⁻¹ as needed
Remifentanyl	<i>Target controlled infusion:</i> Start at 1.5-2ng.ml ⁻¹ and adjust by 0.25-0.5ng.ml ⁻¹ . <i>Simple infusion (mcg.kg⁻¹.min⁻¹):</i> Start at 0.05-0.1mcg.kg ⁻¹ .min ⁻¹ and titrate accordingly (0.025-0.05 increments) alternatively infuse 5-10ml.h ⁻¹ of a 50mcg.ml ⁻¹ solution. Remember that it may take over 5 minutes for the steady state of remifentanyl to be reached.
Midazolam	<i>Intermittent intravenous bolus:</i> Dilute 10mg of midazolam to a total volume of 10ml 0.9% sodium chloride (1mg.ml ⁻¹) and administering 0.5-1mg intravenously as boluses. Diazepam is an alternative.
Morphine	Intermittent intravenous bolus: 0.5-1mg bolus
Fentanyl	Intermittent intravenous bolus: 20-40mcg bolus
Ketamine	Intermittent intravenous bolus: 0.25-0.5mg.kg ⁻¹ bolus

Table 5. Advantages and disadvantages of remifentanyl and propofol sedation

Remifentanyl		Propofol	
Advantages	Disadvantages	Advantages	Disadvantages
Short-acting	Respiratory depression	Short-acting	Respiratory depression
Constant context sensitive half-time	Less effective anxiolysis	Rapid clearance	Haemodynamic instability
Less effective amnesia	Rapid clearance	Dose related sedation time	Variable context sensitive half
Antitussive	Haemodynamic instability (high doses)	Dose related amnesia	No analgesic properties
Analgesic	Muscle rigidity (high doses)	Non dose related anxiolysis	
Sedative	Nausea and pruritus		

LOCAL ANAESTHESIA OF THE AIRWAY

Once sedation has begun, a vasoconstrictor applied nasally will decrease localised blood flow (thus reducing the risk of epistaxis) and prolong the effect of the local anaesthetic (by reducing the rate of absorption). Typical vasoconstrictors are epinephrine (0.1%), ephedrine (0.5%), phenylephrine (0.5%-1%) and xylometazoline (0.05%). 1-2 drops in each nostril should achieve vasoconstriction. Be cautious in patients with pre-existing medical conditions such as hypertension. A combination of vasoconstrictor plus local anaesthetic can be used e.g. Co-Phenylcaine (50mg.ml⁻¹ lidocaine, 5mg.ml⁻¹ phenylephrine).

There are many ways to anaesthetise the airway for fiberoptic intubation. We describe our favoured technique (Table 6), but have also mentioned alternative techniques. The exact choice of technique or combination of techniques is dictated by local availability of drugs and administration devices and by personal choice and experience.

In patients with distorted airway anatomy or friable tumours, invasive nerve blocks should be avoided. Lidocaine may be used in a variety of concentrations; the maximum safe topical dose for airway mucosa has been shown to be up to 9mg.kg⁻¹.⁶

Table 6. Easy steps to anaesthetise the airway

Nasopharynx	Co-Phenylcaine 'sniffed' up both nostrils and Instillagel® to both nares
Oropharynx	Mucosal Atomising Device (MAD) (purpose designed or improvised - see text): 10ml 1% lignocaine
Larynx	Spray-as-you-go 4% lignocaine (2ml x3) down side port of the scope, above the larynx and onto the vocal cords (where available using an epidural catheter)

Box 1. Summary checklist of equipment required for awake fiberoptic intubation

Fully operational scope/TV monitor – set up and checked
 Monitoring equipment/ Resuscitation facilities, Skilled assistant
 Suction apparatus
 Oxygen supply: face mask/nasal sponge, green tubing
 Different types/size ETT's (6.0, 6.5 flexible reinforced ETT's)
 Split oral airway (Berman or Ovassapian)
 IV cannula, glycopyrrolate 4mcg.kg⁻¹
 Co-phenylcaine 2.5mls (to nostril)
 Laryngo-Tracheal Mucosal Atomisation Device
 Epidural catheter 16G (with tip cut off)/open ended catheter
 2% lidocaine gel ('Instillagel') 5ml to mouth to gargle
 1% lidocaine 10ml via MAD over back of tongue directed to larynx
 4% lidocaine 2ml x 3 (in 5ml syringe with 2ml air)
 Warm sterile saline (to soften tube), KY Jelly (nose)
 Saline (lubrication for railroading tube over scope)

Anaesthetising the nasopharynx

The trigeminal nerve provides the sensory fibres to the nasal mucosa via the sphenopalatine ganglion, which also innervates the superior segments of the tonsils, uvula and pharynx. There are different techniques to anaesthetise the nose. Our choice is Co-Phenylcaine followed by Instillagel® (2% lignocaine and chlorhexidine) to the nares.

Lidocaine can sting when applied to mucosal surfaces. However, if topicalisation is commenced at a low concentration and increased to a stronger concentration, it tends to be better tolerated by the patient. Warming the local anaesthetic to body temperature may also reduce the 'stinging' associated with topicalisation.⁵ Also, although topicalisation is applied predominantly into the chosen nostril, a small amount should be applied to the other nostril since there is often some cross-innervation of the nasal septum.

Other alternative methods include:

- 4% cocaine soaked cotton swabs
- nebulised 4% lidocaine (4-6 mls)
- 'Moffets' solution which is 1ml 1:1000 epinephrine, 2ml 1% sodium bicarbonate and 2ml 10% cocaine.

Anaesthetising the oropharynx

The pharynx and posterior third of the tongue are innervated by the glossopharyngeal nerve.

- Mucosal atomiser devices (MAD) are useful to assist in depositing the local anaesthetic as fine droplets. There are several different types of this device available commercially. However a similar effect can be achieved by attaching a 20G cannula to some green oxygen tubing via a three-way tap. The local anaesthetic can then be injected via the cannula port, and an oxygen flow rate of 4-8l.min⁻¹ produces good atomisation (Figure 9). Reassure the patient that coughing may occur during this time.

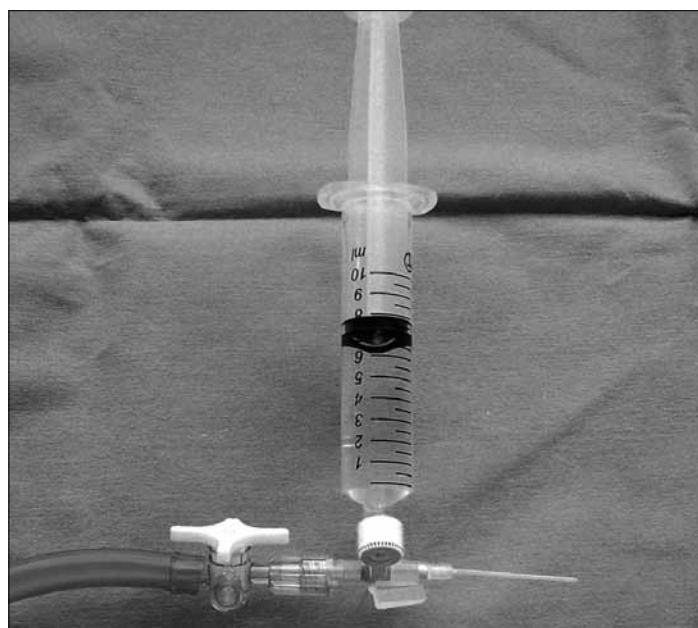


Figure 9. Improvised Mucosal Atomiser Device (MAD)

- A benzocaine lozenge may be used to start the process of anaesthesia.
- Instillagel can be gargled orally to anaesthetise the pharynx, followed by 1% and 4% lidocaine spray.

Anaesthetising the larynx

The final nerve to be anaesthetised is the vagus. This nerve supplies sensory branches both above and below the vocal cords via two main branches. The superior laryngeal nerve supplies the arytenoids, epiglottis and sensation above the cords. Below the cords, the sensory innervation is supplied via the recurrent laryngeal nerve.

The commonest method to anaesthetise the larynx is to spray lignocaine directly down the fibrescope side port (spray-as-you-go technique).

'Spray-as-you-go' technique

This is a technique where the larynx is identified using the fibrescope and anaesthetised as visualised.⁶ A simple method is to inject the local anaesthetic directly down the side port.

However for a more accurate administration of local anaesthetic onto and below the cords an epidural catheter is useful. The epidural catheter is threaded out of the end of the scope and 2ml 4% lidocaine is injected onto the cords (Figure 10). This can either be 'trickled' onto the cords, or a more forceful 'jet' can be achieved by the addition of air into the injecting syringe (with the syringe held vertically pointing downwards). Both techniques will cause the patient to cough and the view of the cords may be temporarily lost, so it is important to remain patient and keep the fibrescope in the same position until the view clears. Make sure that the epidural catheter is retracted after injecting, to avoid airway irritation or scratching by the tip.



Figure 10. Transendoscopic local anaesthetic administration through an epidural catheter

The fibrescope can be advanced closer to the cords and the epidural catheter can often be placed through the cords allowing a further dose of 2ml 4% lidocaine to be injected below the cords. Again coughing is to be expected and the epidural catheter should be withdrawn until the patient settles.

A recent randomised, double-blind comparison of 2% and 4% lidocaine for topical spray-as-you-go anaesthesia demonstrated that

there were no significant differences in systolic blood pressure or pulse at various stages of airway manipulation.⁷ Both produced clinically acceptable intubating conditions for awake fiberoptic intubation. However the total doses and subsequent plasma concentrations were less in the patients who received the 2% dose. This has useful implications for clinical practice from a safety aspect, and in countries where there is no access to 4% lidocaine it is useful to know that lower concentrations can work equally well.

Other techniques include:

Regional nerve blocks

Although regional nerve blocks are frequently described, they are complicated and invasive to perform, and therefore rarely done and will not be discussed further.

Nebulisation of lignocaine

Nebulised 4% lignocaine can also be used as the initial anaesthetic for the airway. One suggested regimen is 5ml over 10-15 minutes. This technique is efficient but may be more time-consuming.

Translaryngeal block

Also known as cricothyroid puncture, this is another method for anaesthetising the larynx. A 20G cannula is inserted through the cricothyroid membrane and after air has been aspirated, 2-3ml 2% or 4% lidocaine is injected, asking the patient to breathe out fully prior to injection. The subsequent inspiration and coughing will disperse the local anaesthetic efficiently. The benefit of using a cannula compared to a needle is that there is reduced risk of trauma during the procedure. Transtracheal injection is a very useful way of topicalising the larynx and trachea if you do not have a fibrescope to direct the local anaesthetic and can produce excellent conditions. It is also very useful if there is an obstructed view of the larynx from above (e.g. by glottic or supraglottic tumour).

Patients who have undergone any of these procedures for airway anaesthesia remain at risk of aspiration into the airway for several hours after the procedure.

BRONCHOSCOPY AND INTUBATION

The operator passes the scope under direct vision through the nose or mouth and into the pharynx. At all times the scope should be held taught and straight. Small movements of the tip of the scope tend to allow the most successful manoeuvring through the airway.

Difficulty may sometimes be caused when patients have a small pharyngeal cavity, due to normal variation in anatomy, receding mandible, or disease causing swelling or oedema. Asking the patient to sniff can enlarge the nasopharyngeal cavity. Asking the patient to 'stick out their tongue or jaw' can improve the view in the lower pharyngeal space. Secretions and misting of the fiberoptic lens may also obscure the view on the end of the scope. Carefully brushing the adjacent mucous membranes with the tip can often clear the view or asking the patient to swallow.

If you get 'lost' or lose the airspace, i.e. your scope is sitting in secretions ('white-out'), or lying against a mucosal surface ('pink-out'), then withdraw slightly until your view is re-established.

Once the epiglottis and cords are visualised (Figure 11) the spray-as-you-go technique can be instigated if this is your technique of choice. The effect of the topical anaesthesia on the cords can be assessed by observing the reactivity of the larynx to the lidocaine spray. An absent or markedly subdued cough usually indicates an adequately anaesthetised larynx.

Asking the patient to take a deep breath often facilitates entry of the scope through the vocal cords. Once through the cords, carefully advance the tip of the scope a reasonable distance beyond the cords, before railroading the ETT over the fibrescope. A small amount of saline administered into the ETT at this point can reduce friction between the scope and the tube. Lubrication (i.e. KY Jelly) should also be applied to the nares and/or the cuff of the ETT, before it is inserted into the nostril (or mouth) and railroaded over the scope. Passing the endotracheal tube through the nostril is one of the potentially more stimulating parts of the procedure for the patient and some reassurance is often required at this point.

Loosen the endotracheal tube connector from the fibrescope handle. A gentle twisting motion should allow the tube to pass without too much force. If resistance is met, it is likely that the tube tip has caught on the arytenoids. A 360° continual rotation or 'drilling' of the tube should overcome any hold-up when using a reinforced tube. With the blue Portex pre-formed tube, a 90-180° anticlockwise rotation (of both the tube and the scope and advancing both together) can usually overcome the hold-up and allow the tube to advance past the arytenoids and through the cords.

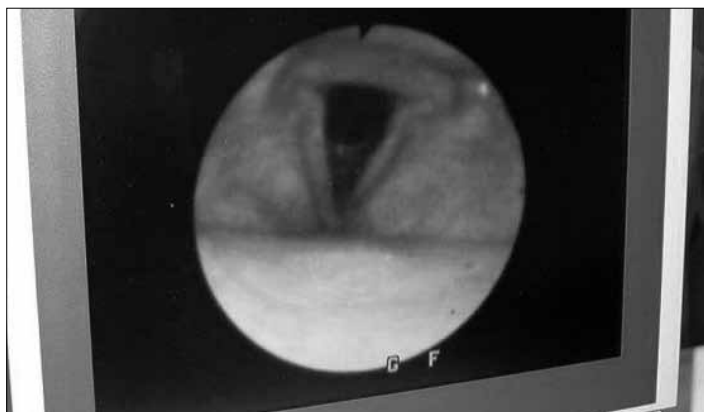

Figure 11. View of the larynx

Advance the endotracheal tube into the trachea over the scope until the tip of the tube is correctly positioned above the carina. Withdraw the fibrescope and attach the circuit to the endotracheal tube. Capnography will also confirm correct placement and general anaesthesia can now be induced. This can be done intravenously or as an inhalational induction. The endotracheal tube cuff should not be inflated until after induction of anaesthesia.

COMPLICATIONS

Operator skill and practice will help to ensure a straightforward and successful intubation. Bleeding from minor trauma can make a potentially difficult airway unnecessarily more complicated. A patient who is coughing may end up with more upper airway bruising than one whose airway reflexes are quiescent. If protracted

coughing occurs it may indicate inadequate anaesthesia or sedation. Both can be adjusted accordingly. Technical failure can be minimised by ensuring all equipment is checked prior to proceeding and the anaesthetist should always be vigilant to the possibility of airway obstruction that may be exacerbated by sedation. Equally a degree of obstruction may occur once the scope enters the larynx or trachea. Remember that an awake tracheostomy may be the most appropriate line of management in patients with extremely critical airways.

Awake fiberoptic intubation is a procedure in which fairly liberal amounts of local anaesthetic may be used (especially if sedation is contraindicated) and this is not without risk. The anaesthetist should be vigilant in monitoring for signs of toxicity and overdose, remembering that peak absorption of topical anaesthesia can occur 15-60 minutes following administration.

Table 7. Complications of awake fiberoptic intubation

Equipment failure	Poor view/fogging
Bleeding/haematoma	Coughing
Complete airway obstruction	Oesophageal intubation
Local anaesthetic toxicity	Failure to pass ETT (intubate)

SUMMARY

Awake fiberoptic intubation performed by a skilled operator allows the airway to be secured safely in situations where conventional laryngoscopy may prove challenging. It is a straightforward technique that, once mastered, is an extremely valuable skill. The key to its success is thorough preparation of the equipment and the patient. Since there is a variety of ways to provide sedation and airway anaesthesia, each individual anaesthetist will adopt a practice with which they feel confident and tailor it to each patient's requirements. Although it is imperative to have an understanding of the principles underlying awake fiberoptic intubation, nothing can replace the experience gained by directly observing and practising the technique.

REFERENCES

1. Ovassapian A, Krejciec TC, Yelich J, et al. Awake fiberoptic intubation in the patient at high risk of aspiration. *Br J Anaesth* 1989; **62**: 13-16.
2. Popat MT. Practical Fiberoptic Intubation. Butterworth-Heinemann. Published 2001.
3. Rai MR, Parry TM, Dombrovskis A et al. Remifentanyl target-controlled infusion vs. propofol target-controlled infusion for conscious sedation for awake fiberoptic intubation: a double-blinded randomized controlled trial. *Br J Anaesth* 2008; **100**: 125-30.
4. Marsland CP, Martin KM, Larsen PD, Segal R; Lidocaine toxicity in volunteer subjects undergoing awake fiberoptic intubation. *Anesth Analg* 2005; **101**: 607.
5. Bell RW & Butt ZA; Warming lignocaine reduces the pain of injection during peribulbar local anaesthesia for cataract surgery. *Br J Ophthalmol* 1995; **79**: 1015-7.
6. Williams KA, Barker GL, Harwood RJ et al. Combined nebulisation and spray-as-you-go topical local anaesthesia of the airway. *Br J Anaesth* 2005; **95**: 549-53.
7. Xue F, Liu H, He N, et al. Spray-as-you-go airway topical anaesthesia in patients with a difficult airway: a randomised, double-blind comparison of 2% and 4% lidocaine. *Anesth Analg* 2009; **108**: 536-43.